

An innovative, safe and sterile sigmoid access (ISSA) for NOTES



Authors

D. Wilhelm^{1,2}, A. Meining³, S. von Delius³, A. Fiolka², S. Can², C. Hann von Weyhern⁴, A. Schneider², H. Feussner^{1,2}

Institutions

¹ Department of Surgery, Klinikum r. d. Isar, Technical University, Munich, Germany

² Workgroup for minimal invasive Surgery MITI, Klinikum r. d. Isar, Technical University, Munich, Germany

³ 2nd Medical Department, Klinikum r. d. Isar, Technical University, Munich, Germany

⁴ Institute for Pathology, Klinikum r. d. Isar, Technical University, Munich, Germany

submitted 22 February 2007
accepted after revision
 22 March 2007

Bibliography

DOI 10.1055/s-2007-966438
 Published ahead of print
Endoscopy 2007; 39:
 1–6 © Georg Thieme
 Verlag KG Stuttgart · New York
 ISSN 0013-726X

Corresponding author

H. Feussner, MD

Department of Surgery
 Klinikum r. d. Isar
 Technical University Munich
 Munich
 Germany
 Fax: ■
 feussner@chir.med.
 tu-muenchen.de

Background and study aims: The use of a transcolonic approach for natural orifice transluminal endoscopic surgery (NOTES) offers relevant advantages compared with a transgastric procedure. However both techniques are still limited by specific shortcomings that need to be resolved before the transluminal approach can be translated to human applications. In this article we describe an innovative method for a transcolonic procedure, which might represent the next step forward in NOTES.

Patients and methods: In three acute and five survival porcine models we evaluated a specially designed guide tube, which is inserted via a transcolonic approach into the abdominal cavity after intraperitoneal instillation of a decontamination solution. After endoscopic evaluation of the abdomen the closure of the entry site was performed surgically. Main parameters obtained in the study were the feasibility and safety of the

approach, the bacterial contamination due to the transcolonic procedure, and the safe closure of the entry site. Animals in the survival model were euthanized 10 days after the procedure.

Results: The transcolonic approach took place without complications. There was no bleeding or laceration of adjacent organs. The surgical closure guaranteed a leak-proof closure of the entry site. All pigs in the survival model showed an excellent postinterventional course. At necropsy, the colonic incision sites were completely closed and appeared well healed. No abscesses or any sign of inflammation could be identified.

Conclusions: The transcolonic approach using an innovative guide tube is feasible and safe. The technique described offers mentionable advantages and therefore reduces the known shortcomings of NOTES. However, further studies are needed to approve our results of an initial evaluation.

Background

The use of natural orifices of the human body to access the abdominal cavity (natural orifice transluminal endoscopic surgery [NOTES]) is, at this time, the most promising method of reducing further trauma. It allows surgical treatment without any incision of the abdominal wall, and therefore aims to further reduce the known drawbacks of open surgery, such as postoperative pain, wound infection, and incisional hernias. Since it was first described by Kalloo et al. in 2004 [1], many other groups have performed similar procedures using a transgastric approach to enter the peritoneal cavity for diagnostic purposes and to treat intra-abdominal organs such as the gallbladder [2,3], stomach [4,5], uterus [6], and fallopian tubes [7].

Using the transgastric approach, an endoscope is generally inserted transorally and advanced

through the anterior wall of the stomach into the abdomen. Unfortunately the forerun to the stomach is somewhat long, which limits the usable length of the scope. Additionally, the inverted scope offers only a limited view of the upper abdomen and makes manipulation on its organs more complex. The second obstacle to overcome in transluminal surgery is the lack of a practicable sealing method for the entry site [8,9]. For these reasons access routes other than the transgastric approach are of high interest. Fong et al. were the first to describe a transcolonic advancement, but compared with the transgastric approach this technique was associated with an increased bacterial contamination rate of the abdominal cavity [9].

Further work is also required to optimize the preconditions for organ manipulation [3,10] and to identify the optimal approach for particular interventions [11–13].

We developed an innovative sigmoid approach in order to reduce the risk of laceration of intra-abdominal organs and to enable sterile introduction of the flexible endoscope. This approach additionally enables the leak-proof closure of the entry site, and therefore offers an interesting alternative to known techniques. In this article we describe the exact technique of the trans-sigmoid approach and our first experience of an acute and a survival porcine model.

Material and methods

Evaluation of the innovative trans-sigmoid access was based upon three acute and five survival porcine models. In the non-survival model, all pigs were sacrificed after completion of the intervention, and necropsy was carried out immediately, whereas in the survival model, observation over 10 days was followed by euthanasia and subsequent necropsy. The study protocol of the latter model was approved by the commissioner of animal welfare of the Government of Upper Bavaria.

Preparation

All animals were regularly fed until 24 hours before the procedure. Subsequently, they received a liquid diet until 12 hours before the intervention.

Pre-anesthesia sedation was achieved with an intramuscular injection of azaperon (2.0 mg/kg), atropin (0.02 mg/kg) and ketamine (15 mg/kg). General anesthesia was initiated by the injection of etomidate (1–2 mg/kg). After endotracheal intubation and throughout surgery, maintenance of anesthesia was achieved by continuous inhalation of isoflurane with bolus application of fentanyl. Before performing the trans-sigmoid approach, an antibiotic (1000 mg ampicillin + 500 mg sulbactam) was administered to all pigs.

The animals were positioned in a supine position, with the hind legs fixed in an extended position. The anorectum was cleaned by the administration of tap-water enemas and repeated irrigation with sterilized isotone fluids. Additionally, and after sealing the sigmoid orally with a swab serving as a plug, the end bowel was decontaminated by the use of a mucosal disinfection solution (Octenisept®, Schülke & Mayr, Norderstedt, Germany), which remained in situ for at least 5 minutes. The perianal region was additionally prepared using propranolol disinfection and then covered with sterile drapery.

NOTES procedure

The main procedure consists of four consecutive steps.

1 Instillation of the protective fluid. First, a fluidoperitoneum is established using a sterile Verres needle, which is inserted below the navel, taking the usual precautions necessary for laparoscopic interventions. Via this needle, 1 L of taurolidin solution (Taurolin®, Boehringer Ingelheim, Ingelheim, Germany) and 2.5 L of Ringer solution are installed into the abdominal cavity. Taurolidin solution is a decontaminating fluid widely used in general surgery for the prevention and therapy of peritonitis. The pigs are then positioned in an anti-Trendelenburg position (head raised up 30°). As the injected fluid will mainly collect in the small pelvis, the mobile and gas-containing content of the pelvis will be separated from the pelvic floor and the rectosigmoid. The fluid leads to an internal excavation of the rectosigmoid (rectocele), which serves as the entry point later on (► **Figure 1**).

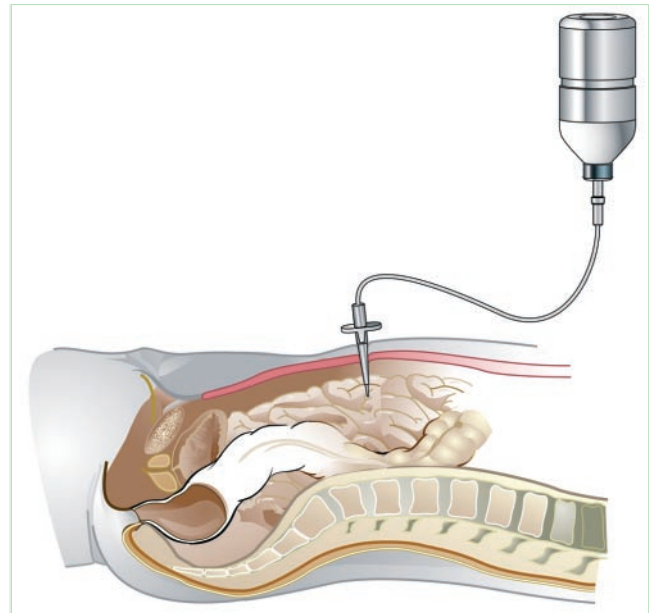


Figure 1 Instillation of 1 L of taurolidin solution and 2.5 L of Ringer solution into the peritoneal cavity. In a 30° reverse Trendelenburg position, the bowel is floating on top of the artificial ascites. Thus, a safety area is created around the future entry point.

2 Identification and preparation of the entry point. First, a rigid endoluminal ultrasound probe (10 MHz) is inserted transanally to verify a sufficient amount of artificial ascites in the pelvis, with the small bowel and major vessels at some distance from the potential entry point. Then the rectosigmoid is entered using a modified device for transanal endoscopic microsurgery (TEM; Storz, Tuttlingen, Germany). The ventral aspect of the rectosigmoid junction (about 12–15 cm from the anal verge) and the resulting rectocele are identified and marked with a short application of diathermy. A purse string suture is then placed around the future entry point to seal the bowel wall after the procedure (► **Figures 2 a, b**).

3 Introduction of the guide tube. The front plate of the TEM device is removed with the tube itself left in place. Via the TEM tube, a specially designed, sterilized endoscopic guide is introduced (► **Figures 3 a, b**). Using the sharp tip, the entry point is perforated, giving entry into the abdominal cavity. Then the endoscopic guide is advanced, and as soon as the peritoneal cavity is intruded, the inlay is slowly removed. The outer end of the guide tube is connected to an airtight valve unit, and a gas-sterilized flexible endoscope (Olympus CF 140 I, Olympus GmbH, Hamburg, Germany) is inserted via the guide tube into the abdomen to perform further intervention (► **Figures 3 a, b**).

4 Removal of the guide tube, closure of the entry site. After the inspection of the peritoneal cavity and removal by suction of the intra-abdominal fluid and air, the flexible endoscope is withdrawn with the guide tube. Under visual control, the purse string suture is closed. Finally, the small nipple resulting from the purse string is additionally secured by the application of a linear stapler (► **Figure 4**). After digital rectal examination and verification of a leak-proof closure the intervention is finished.

Endoscopy

To assess the value of the trans-sigmoid approach, we aimed to inspect at least both upper abdominal quadrants including liver, spleen, and gallbladder. This was done once through the artifi-

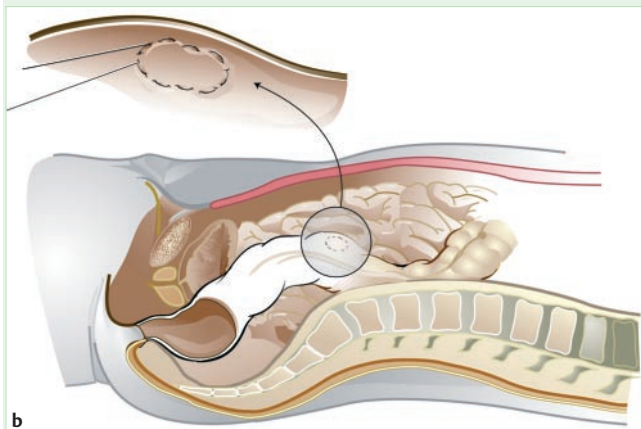
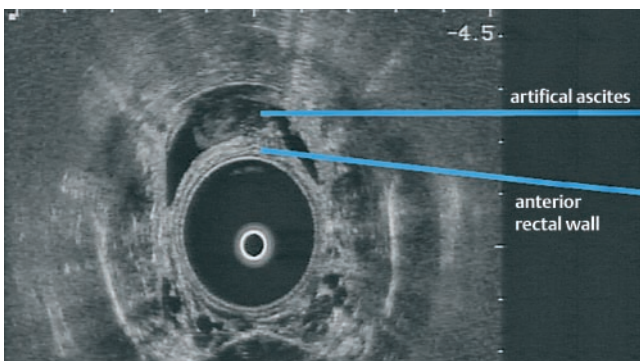


Figure 2 **a** The entry point is identified by transrectal ultrasound. At the height of the rectum, where fluid keeps the bowel loops apart, a safe access to the abdominal cavity should be possible. **b** The site formerly identified by transrectal ultrasound is encircled by a purse string suture (inset).

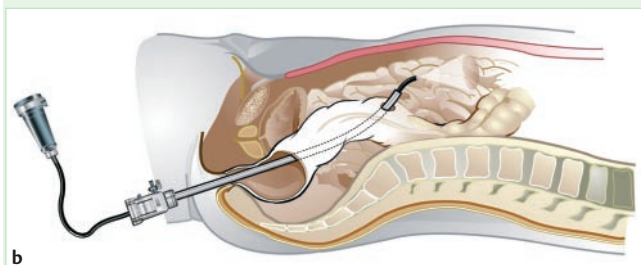
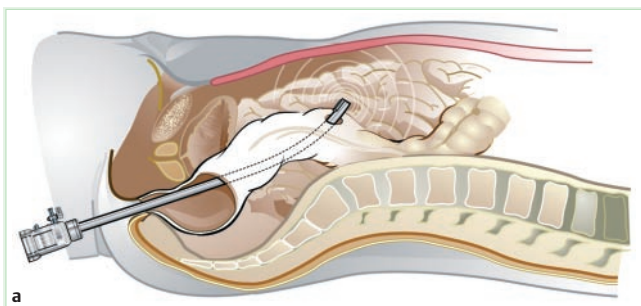


Figure 3 **a** A specially designed, sterilized trocar is inserted into the abdominal cavity by perforating the area of the rectal wall "fenced in" by the purse string suture. **b** After removal of the obturator, the flexible endoscope can be passed through the sterile interior of the trocar into the abdomen. Even if the endoscope is repeatedly advanced and pulled back, bacterial ascension is excluded.

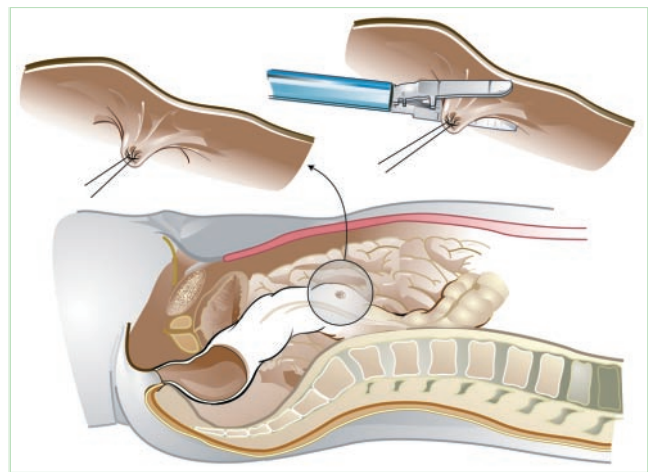


Figure 4 At the end of the procedure, the purse string suture is immediately closed after withdrawal of the trocar. The slight elevation of the rectal wall resulting from the purse string suture is excised by one or two applications of the linear stapling device (inset). Thus, a tight and reliable closure of the former entry site is achieved.

cial ascites, and once more in air-filled surroundings following extraction of the fluid by suction. Standard endoscopic manipulations, such as rotation, torque, retroflexion, and tip deflection were mandatory. Examination took place for at least 30 minutes to simulate clinical conditions and to receive valuable results for potential bacterial contamination. All examinations were performed by a highly experienced endoscopist and recorded using a digital video device for postprocessing afterwards.

To evaluate immediate bacterial contamination, surface swabbings were taken from the tip of the guide tube when extracted.

Postoperative care

After the interventions, the acute porcine model pigs were sacrificed by a lethal dose injection of pentobarbitone and potassium chloride. Necropsy was carried out to identify laceration of surrounding organs, signs of bleeding, and to examine the entry site for leaks.

For the survival porcine model the postoperative care was as follows. Soon after the procedure, postoperative analgesia was given by intravenous administration of 4 mg/kg carprofenum and then an equivalent oral analgesia over 2 days. Additionally all pigs received antibiotic therapy with peroral enrofloxacin (1.7 mg/kg) during the first 2 postoperative days.

All pigs were examined daily for signs of infection, and temperature was recorded twice a day. All animals were allowed free oral feeding the day after the intervention. On the tenth day, the pigs were weighed and finally sacrificed. During the postmortem analysis the abdominal cavity was inspected for signs of infection, bleeding, perforation, or peritonitis. As soon as the peritoneum was opened, surface swabbings were taken for microbiologic testing. Inspection of the peritoneal cavity was performed with particular focus on the entry point and adjacent structures in order to identify any leakage, fistula, adhesion, or laceration. The rectosigmoid was excised in accordance with usual surgical techniques and further examined. In addition, tissue specimens from the entry site were obtained for histopathologic examination.

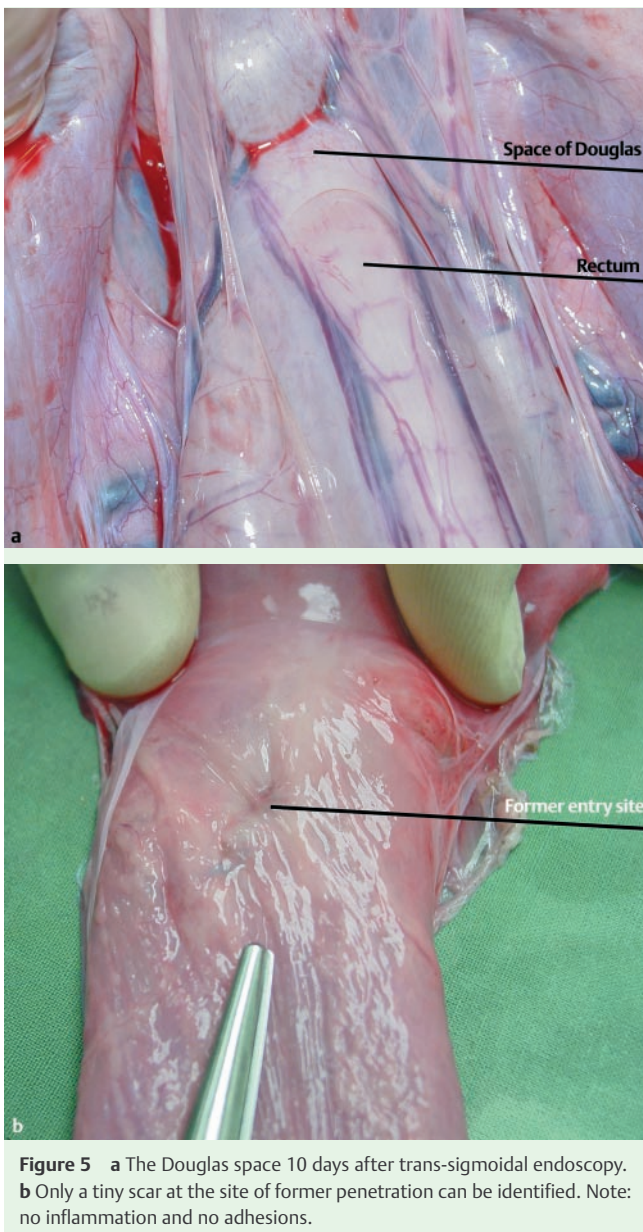


Figure 5 **a** The Douglas space 10 days after trans-sigmoidal endoscopy. **b** Only a tiny scar at the site of former penetration can be identified. Note: no inflammation and no adhesions.

Histopathology

Following resection, localization, and inspection of the entry point, resected specimens were fixed in neutral buffered formalin. The entry region was removed and embedded in paraffin. Thereafter, serial sections (5 μ m) were cut and stained with hematoxylin and eosin.

Results

Trans-sigmoid approach

The trans-sigmoid approach was technically feasible in all animals. An adequate entry point could be identified by the help of direct inspection and endoluminal ultrasound in each case. The incision of the rectosigmoid could be performed in all animals without relevant immediate complications. In one case the prepared purse string suture was cut while inserting the guide tube; the closure was consequently hand-guided and additional staples were applied, resulting in no leakage or fistula. The guide tube could always be easily advanced into the peritoneal cavity,

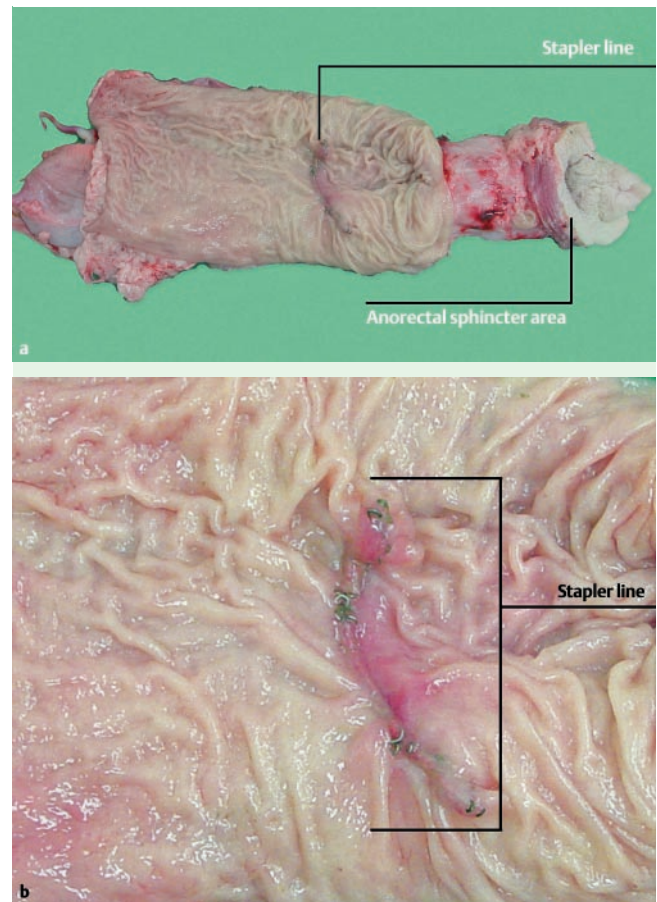


Figure 6 **a** Resected rectosigmoid specimen. The sphincter region is left intact. The rest of the specimen is opened. The stapler line is located well within the peritoneal cavity. **b** Endoluminal view to the entry site. Normal aspect of the stapler line without macroscopic inflammation or signs of leakage.

and, after connection to the valve unit, direct introduction of the endoscope was possible. Additionally, as the guide tube had an angled tip, it permitted the scope to be steered by simply rotating the tube. Endoscopic manipulation was not impaired by the guide tube. Depending on the position of the animal (Trendelenburg/reverse Trendelenburg) herniation of the small bowel occurred during withdrawal of the scope in some cases. This could be easily avoided by insufflating a small amount of air when withdrawing the endoscope and did not result in any drawback during the series.

The average time to complete the procedure was 9.3 minutes (± 1.3) for the incision process, and 7.8 minutes (± 2.3) for the withdrawal of the scope and closure of the entry site. The most time-consuming part was the induction of the fluidoperitoneum through the Verres needle, which took 20–30 minutes.

Transluminal endoscopy

Visualization of the upper abdomen (including spleen and the larger curvature of the stomach) was excellent, either directly through the artificial ascites or after insufflation of air. Amazingly there was no visual alteration caused by blood-polluted ascites, and visualization was excellent from the very beginning of the procedure. Identification of the liver, spleen, and stomach could be achieved within moments, and direct access to the gallbladder was possible within 2 minutes without the need for retroflexion. With retroflexion, the colonic entry site and the urin-

ary bladder could be visualized in two animals. Uterine and retroperitoneal structures could not be visualized.

Postoperative survival

There were no deaths, with almost all animals showing an excellent condition during the observation period. Only one pig had a delayed recovery over 2 days, but was asymptomatic within the third day. The mean increase of weight was 9.5 kg (\pm 1.4 kg) with the starting weight calculated at about 50 kg (\pm 3 kg). All animals had regular bowel function with defecation starting at a median of the second postoperative day. The pigs ambulated freely and showed normal behavior without any signs of distress.

None of the animals developed fever, though subfebrile temperatures were measured in two of the five pigs on the first postoperative day.

Necropsy

During the postmortem examination there were no signs of infection or peritonitis; this was confirmed in microbiologic testing, with no bacterial growth after 48 hours. In two pigs a clear, thick bubbled foam was identified between the small bowel segments, which probably resulted from taurolidin instillation. There were no significant adhesions to the peritoneal layer.

The entry sites in most cases could hardly be identified on the peritoneal aspect of the colon and appeared as well-healed, pale scars as the only remnant of the former artificial perforation (► **Figures 5 a, b**).

There were no signs of perforation or fistula in the macroscopic or microscopic examination. In histopathologic postprocessing there were no intramural microabscesses; the perforation side presented as chronic inflammatory reaction with the beginnings of fibroplastic invasion. As necropsy showed, all entry points were located with an almost identical distance to the anorectum (mean distance 12.4 cm (\pm 2.3 cm) (► **Figure 6 a**). There was no major bleeding observed during the insertion part of the procedure, and no organ damage was identified.

The closure of the entry site was successful in all animals and resulted in a leak-proof seal without any narrowing of the lumen (► **Figure 6 b**). The closure could normally be achieved using only one stapler magazine, with only two animals requiring an additional stapler magazine.

Discussion

Transluminal endoscopic interventions via so-called natural orifices are gaining increasing interest as they allow surgical treatment without any incision of the abdominal wall. NOTES is supposed to further reduce the invasiveness of transabdominal surgery by eliminating abdominal incisions and multiple trocar puncture sites [14]. Several working groups have demonstrated the feasibility of transgastric surgery with flexible endoscopes. A technical limitation of this method is the need for awkward retroflexion to visualize structures and to perform therapeutic manipulations in the upper abdomen [3, 6, 15]. In particular, the ability to identify, manipulate, and resect the gallbladder has proven to be technically challenging [3, 16]. Moreover, it has been mentioned, that the maximum size of a transgastrically, transesophageally, and finally transorally extracted specimen is naturally restricted [17].

To overcome the obstacles encountered through a transgastric incision, a transcolonic approach that provides an en face orien-

tation to organs in the upper abdomen for better visualization and scope stability was first employed by the Boston group [2, 9]. As with any other surgical access to the abdomen, such an approach should fulfill specific preconditions: (1) facilitating direct access to the target region; (2) permitting a simple, straightforward introduction of instruments; (3) avoiding bacterial contamination while entering the abdominal cavity; (4) enabling an easy-to-achieve and reliable closure of the entry point; and (5) avoiding postoperative complications such as adhesions or strictures. Up to now, investigators encountered peritonitis in one animal and multiple cases of adhesions, although in a limited number of study subjects [2, 9].

In our series on survival following the transcolonic approach, we observed neither of these drawbacks. These advances may be due to several modifications made and additional precautions taken. Prior to the colonic incision we instilled taurolidin solution, a decontaminating fluid widely used in general surgery for the prevention and therapy of peritonitis, into the abdominal cavity. As we encountered three (out of five) positive peritoneal swabs immediately after entering the abdominal cavity this precautionary measure might have been crucial for the prevention of bacterial spread followed by peritonitis or localized inflammation with adhesions. The usage of a sterilized guide tube might have also contributed to the safety of the procedure with regard to infection. We believe that procedures requiring multiple intubations such as cholecystectomy would profit even more, as repeated passages along colonic mucosa could be avoided. Lastly, the full-thickness apposition and surgical closure of the entry point led to reliable leak-proof sealing of the colonic wall without compromising the lumen. We consider the surgical approach advantageous compared with clip closure, as the latter may become insufficient due to mechanical extension of the relatively thin-walled colonic incision, as mentioned previously [9, 18]; the circumscribing purse string at the incision site provided additional support by sealing the incision around the guide tube during the procedure.

Incision of the colonic wall was performed after creating a rectocece under direct visual control. Additional safety was obtained by applying rectal ultrasonography to ensure a safe distance to adjacent organs before advancing the guide tube.

Although we did not perform interventions in the upper abdomen, the transcolonic approach principally eased access to organs in the upper abdomen. In conformity with Fong et al. [9] the liver, gallbladder, and spleen were quickly and easily identified in all pigs, whereas lower abdominal and pelvic structures were poorly seen. The intra-abdominal part of the guide tube provided additional stabilization of the endoscope. Moreover, maneuverability of the endoscope was enhanced by the angulated tip of the guide tube.

In conclusion, we demonstrated that the transcolonic approach to the peritoneal cavity with systematic abdominal exploration is feasible and safe. The use of preprocedural intra-abdominal instillation of a decontaminating fluid, the application of a sterilized guide tube, and the surgical closure of the entry point resulted in a procedure with nearly no complications in our series. Furthermore, enhanced maneuverability and stabilization was provided by the intra-abdominal part of the guide tube. Future studies in the animal model are mandatory for evaluation of our innovative, safe, and sterile sigmoid access (ISSA) for NOTES procedures in the upper abdomen before translation to human applications.

Competing interests: None

References

- 1 *Kaloo AN, Singh VK, Jagannath SB et al.* Flexible transgastric peritoneoscopy: a novel approach to diagnostic and therapeutic interventions in the peritoneal cavity. *Gastrointest Endosc* 2004; 60: 114–117
- 2 *Pai RD, Fong DG, Bundga ME et al.* Transcolonic endoscopic cholecystectomy: a NOTES survival study in a porcine model (with video). *Gastrointest Endosc* 2006; 64: 428–434
- 3 *Park PO, Bergstrom M, Ikeda K et al.* Experimental studies of transgastric gallbladder surgery: cholecystectomy and cholecystogastric anastomosis (videos). *Gastrointest Endosc* 2005; 61: 601–606
- 4 *Bergstrom M, Ikeda K, Swain P, Park PO.* Transgastric anastomosis by using flexible endoscopy in a porcine model (with video). *Gastrointest Endosc* 2006; 63: 307–312
- 5 *Kantsevov SV, Jagannath SB, Niiyama H et al.* Endoscopic gastrojejunostomy with survival in a porcine model. *Gastrointest Endosc* 2005; 62: 287–292
- 6 *Wagh MS, Merrifield BF, Thompson CC.* Survival studies after endoscopic transgastric oophorectomy and tubectomy in a porcine model. *Gastrointest Endosc* 2006; 63: 473–478
- 7 *Jagannath SB, Kantsevov SV, Vaughn CA et al.* Peroral transgastric endoscopic ligation of fallopian tubes with long-term survival in a porcine model. *Gastrointest Endosc* 2005; 61: 449–453
- 8 *Ryou M, Pai R, Sauer J et al.* Evaluating an optimal gastric closure method for transgastric surgery. *Surg Endosc* 2007; 21: 677–680
- 9 *Fong DG, Pai RD, Thompson CC.* Transcolonic endoscopic abdominal exploration: a NOTES survival study in a porcine model. *Gastrointest Endosc* 2007; 65: 312–318
- 10 *Ko CW, Kalloo AN.* Per-oral transgastric abdominal surgery. *Chin J Dig Dis* 2006; 7: 67–70
- 11 *Lima E, Rolanda C, Pego JM et al.* Transvesical endoscopic peritoneoscopy: a novel 5 mm port for intra-abdominal scarless surgery. *J Urol* 2006; 176: 802–805
- 12 *Rolanda C, Lima E, Pego JM et al.* Third-generation cholecystectomy by natural orifices: transgastric and transvesical combined approach (with video). *Gastrointest Endosc* 2007; 65: 111–117
- 13 *Rolanda C, Lima E, Correia-Pinto J.* Searching the best approach for third-generation cholecystectomy. *Gastrointest Endosc* 2007; 65: 354
- 14 *Bhojru S, Vierra MA, Nezhath CR et al.* Trocar injuries in laparoscopic surgery. *J Am Coll Surg* 2001; 192: 677–683
- 15 *Wagh MS, Merrifield BF, Thompson CC.* Endoscopic transgastric abdominal exploration and organ resection: initial experience in a porcine model. *Clin Gastroenterol Hepatol* 2005; 3: 892–896
- 16 *Swanstrom LL, Kozarek R, Pasricha PJ et al.* Development of a new access device for transgastric surgery. *J Gastrointest Surg* 2005; 9: 1129–1136; discussion 1136–1137
- 17 *Lamade W, Hochberger J.* Transgastric surgery: avoiding pitfalls in the development of a new technique. *Gastrointest Endosc* 2006; 63: 698–700
- 18 *Merrifield BF, Wagh MS, Thompson CC.* Peroral transgastric organ resection: a feasibility study in pigs. *Gastrointest Endosc* 2006; 63: 693–697